

## Cystic hygroma and the importance in its prenatal diagnosis

Higroma cístico e a importância no seu diagnóstico pré-natal

Higroma quístico y la importancia en su diagnóstico prenatal

### Arévalo Suárez Yuli Alexandra

<https://orcid.org/0000-0002-6423-4709> 

Professor at Technical University of Ambato, Ecuador.  
Master's in care management mention in emergency  
units and intensive care units  
[ya.arevalo@uta.edu.ec](mailto:ya.arevalo@uta.edu.ec)

### Espinosa Benítez Quenia Lorena

<https://orcid.org/0000-0002-9565-3009> 

Professor at Technical University of Ambato, Ecuador.  
Master in health management for local development  
[ql.espinosa@uta.edu.ec](mailto:ql.espinosa@uta.edu.ec)

### Masabanda Poaquiza Patricia Elisabeth

<https://orcid.org/0000-0001-5624-1450> 

Professor at Technical University of Ambato, Ecuador.  
Master's Degree in Surgical Nursing  
[pe.masabanda@uta.edu.ec](mailto:pe.masabanda@uta.edu.ec)

### Rodríguez Gamboa Mery Susana

<https://orcid.org/0000-0003-3444-2934> 

Professor at Technical University of Ambato, Ecuador.  
Master's degree in surgical nursing  
[ms.rodriguez@uta.edu.ec](mailto:ms.rodriguez@uta.edu.ec)

### Venegas Mera Beatriz

<https://orcid.org/0000-0002-1270-7113> 

Professor at Technical University of Ambato, Ecuador.  
Master's degree in surgical nursing  
[ve.venegas@uta.edu.ec](mailto:ve.venegas@uta.edu.ec)

### ARTICLE HISTORY

**Received:** 10-05-2023

**Revised Version:** 19-07-2023

**Accepted:** 24-07-2023

**Published:** 30-07-2023

**Copyright:** © 2023 by the authors

**License:** CC BY-NC-ND 4.0

**Manuscript type:** Article

### ARTICLE INFORMATIONS

**Science-Metrix Classification (Domain):**

Health Sciences

**Main topic:**

Cystic hygroma

**Main practical implications:**

It provides important insights to better understand the problem, diagnosis and treatment of cystic hygroma in newborns.

**Originality/value:**

It presents an exhaustive review of the literature to guide new studies on the problem addressed.

### ABSTRACT

**Introduction:** Cystic hygroma is a congenital malformation of the lymphatic system that presents as single cavities filled with fluid, more frequently at the cervical level and can be associated with genetic syndromes and malformations. **Objective:** To carry out a systematic review through the study of cystic hygroma and its importance in its prenatal diagnosis. **Methodology:** A qualitative systematic review of the studies focused on cystic hygroma was carried out. Literature search techniques included search engines such as Medline (Pubmed), Scielo, Elsevier. A total of 20 items are included. **Results:** Cystic hygromas are endothelial cell-covered cysts that arise from lymphatic malformations. Many of them affect the cervical lymph nodes and occur in the neck region. Other preferred locations are the axilla, mediastinum, groin, and retroperitoneal area, where these cystic lesions are present at birth. **Conclusions:** The importance of prenatal diagnosis methods are fundamental to know the potential problems that the R.N. after his birth.

**Keywords:** Hygroma; prenatal; diagnosis; newborn.

### RESUMO

**Introdução:** O higroma cístico é uma malformação congênita do sistema linfático que se apresenta como cavidades únicas preenchidas por líquido, mais frequentemente ao nível cervical e pode estar associada a síndromes e malformações genéticas. **Objetivo:** Realizar uma revisão sistemática através do estudo do higroma cístico e sua importância no diagnóstico pré-natal. **Metodologia:** Foi realizada uma revisão sistemática qualitativa de estudos focados em higroma cístico. As técnicas de busca de literatura incluíram mecanismos de busca como Medline (Pubmed), Scielo, Elsevier. Um total de 20 itens estão incluídos. **Resultados:** Os higromas císticos são cistos recobertos por células endoteliais que surgem de malformações linfáticas. Muitos deles afetam os gânglios linfáticos cervicais e ocorrem na região do pescoço. Outros locais preferidos são a axila, mediastino, virilha e área retroperitoneal, onde essas lesões císticas estão presentes ao nascimento. **Conclusões:** A importância dos métodos de diagnóstico pré-natal são fundamentais para conhecer os potenciais problemas que o R.N. depois de seu nascimento.

**Palavras-chave:** Pediátrico, leucemia, cuidador, enfermagem.

### RESUMEN

**Introducción:** El higroma quístico es una malformación congénita del sistema linfático que se presenta como cavidades únicas llenas de líquido, más frecuentemente a nivel cervical y puede asociarse a síndromes genéticos y malformaciones. **Objetivo:** Realizar una revisión sistemática a través del estudio del higroma quístico y su importancia en su diagnóstico prenatal. **Metodología:** Se realizó una revisión sistemática cualitativa de los estudios centrados en el higroma quístico. Las técnicas de búsqueda de literatura incluyeron motores de búsqueda como Medline (Pubmed), Scielo, Elsevier. Se incluyen un total de 20 artículos. **Resultados:** Los higromas quísticos son quistes cubiertos de células endoteliales que surgen de malformaciones linfáticas. Muchos de ellos afectan los ganglios linfáticos cervicales y ocurren en la región del cuello. Otras ubicaciones preferidas son la axila, el mediastino, la ingle y el área retroperitoneal, donde estas lesiones quísticas están presentes al nacer. **Conclusiones:** La importancia de los métodos de diagnóstico prenatal son fundamentales para conocer los problemas potenciales que el R.N. después de su nacimiento.

**Palabras clave:** Higroma; prenatal; diagnóstico; recién nacido.

## INTRODUCTION

"Cystic hygroma is known as a congenital malformation of the lymphatic system that presents as single or multiloculated cavities filled with fluid, most frequently at the cervical level and can be associated with genetic syndromes and chromosomal abnormalities" (Mukakala AK. et al. 2020 .p.).

Within a historical context, Hygroma is derived from the Greek as a water-containing tumour, which are congenital malformations of the lymphatic system. In this sense, cystic hygroma is more frequent than other types of lymphangioma, and can be formed by single or multiple macrocystic lesions with little communication with normal lymphatic channels (Barrientos S. et al. 2017. p .).

According to Mukakala A. et al. (2020) p. says: Thus, a cystic hygroma is a fluid-filled sac (cyst) that forms, in most cases, in the baby's neck due to a malformation or obstruction of the lymphatic system. The lymphatic system is a collection of tissues and organs that move lymph fluid (a watery fluid filled with white blood cells) through the bloodstream and circulatory system to remove waste and toxins.

Additionally, cystic hygromas can manifest anywhere on the body. Common locations are the cervicofacial regions (especially the posterior cervical triangle), the axilla, the mediastinum, the groin, and under the tongue. Likewise, these malformations can occur in the liver, spleen, kidney and intestine. The omental cyst in the omentum and the mesenteric cyst in the mesentery of the intestine represent parallel lesions in these locations (Taqua R. et al. 2018. p .).

Cystic hygromas are rare, accounting for 6% of all benign lesions in infancy and early childhood; however, they are the subtype of lymphangioma that can cause serious lesions and, if not detected in time, contribute to malformations and conditions in the newborn (Pan M. et al. 2020. p .).

Thus, 50% of these lesions are present from birth, and the remaining 50% appear before 2 years of age. However, it has been verified that up to 90% of cases are diagnosed in infants under 2 years of age, and most are diagnosed between 3 and 5 years of age. Likewise, of all cystic hygroma lesions, between 75 and 90% are cervical, 20% are axillary, and the rest are inguinal, retroperitoneal, and thoracic (Torres G. et al. 2014. p .).

As explained in relevant literature, in approximately 80% of cases, the location of cystic hygromas is the cervicofacial region. Therefore, cystic hygroma should always be considered first in the preliminary differential diagnosis of cystic lesions with onset at birth, in the mentioned location. More than 60% of cystic hygromas appear at birth and up to 90% manifest before two years of age (Huamán M. et al. 2018. p .).

"Under this background, prenatal diagnosis of cystic hygromas is usually obtained in the first trimester or early in the second and is not particularly difficult and is reliably performed by transabdominal ultrasound" (Yakıştıran B. et al. 2020. p.) .

According to Torres G. et al. (2014). p. However, the sonographic features of fetal cystic hygroma are much more subtle in the first trimester, as first trimester hygromas differ in that the degree of cystic changes is not as well established, septations are less likely to be seen, and the early signs of its development are most likely to be recognized as a simple raised membrane-like thickening clearly separated from the posterior angles of the fetal cervixes, in light of which the first trimester hygroma can be well established by transvaginal ultrasonography

According to Barrientos S. et al. (2017). p.:Now single or multiple cysts found in the occipitocervical region and due to the presence of multiple septa have a typical honeycomb appearance. Cystic hygromas are associated with an increased risk (59-73%) of fetal chromosomal abnormalities. In addition, in the second trimester, cystic hygromas often progress to dropsy and in the worst case cause fetal death. Thus, the prognosis for fetuses with cystic hygroma, especially in the presence of hydrops, is poor.

On clinical examination, these lesions appear soft, compressible, nontender, transluminant, and without a bruit. Ultrasonography of the lesion usually shows a multicystic lesion with internal septations and no blood flow is detected on color Doppler ultrasound (Romero D. Atobe O. 2016. p.).

After Utomo M. Harahap A, Etika R. (2021). p.. CT shows a multicystic, homogeneous, non-invasive density with low attenuation. These modalities are often helpful in determining the extent of the lesion and its association with nerves and vessels, and are particularly helpful when contemplating surgical management of the lesion. These cysts may produce a milky, serous, sero-bloody, or straw-colored fluid when aspirated with a large-gauge needle.

Cystic hygromas can show up during pregnancy on an ultrasound or after the baby is born as a lump or bump under the skin. If the hygroma appears during pregnancy, there is a risk of abortion or that the baby is stillborn (Torres G. et al. 2014. p .).

Various imaging modalities such as ultrasound, computed tomography, or magnetic resonance imaging are used to

confirm the diagnosis. Ultrasound is the least invasive of all and usually shows multicystic lesions with internal septations. CT and MRI can be useful to further delineate the lesion and to plan surgery, as they help to illustrate the involvement and proximity to neighboring structures ( Joyful P. Toko M. Cary N. 2020. p ).

The prognosis of a patient with a cystic hygroma will largely depend on the anatomic site and whether or not the patient develops secondary complications. Cystic hygromas diagnosed prenatally often have a poorer prognosis than those diagnosed after birth. Surgical excision is usually successful with complete resolution as long as the mass is completely excised; however, the surgical excision rate can be as high as 53% in some cases, which can be improved by the use of adjuvants, such as sclerosing agents (Neira J. Coronel J. Paredes D. 2020. p ).

The nursing staff is also a vital member of the interprofessional team, as they will monitor the patient's vital signs and assist in patient and family education. In the postoperative period for pain and wound infection, the pharmacist will ensure that the patient receives appropriate analgesics, antiemetics, and antibiotics (Utomo M. Harahap A, Etika R. 2021. p.).

To avoid negative consequences associated with this condition, they must be promptly diagnosed and treated. This activity describes the evaluation and treatment of cystic hygromas and highlights the role of the interprofessional team in the evaluation and treatment of patients with this condition. Thus, the objective of this article is to review the available evidence on cystic hygroma, especially with regard to its importance in prenatal diagnosis, as well as current recommendations for its evaluation, case studies, and theoretical foundations.

## METHODS

In order to comply with the objective of the research, an exhaustive search for information has been carried out to carry out a systematic analysis based on scientific and bibliographic evidence from various sources of scientific and high-impact journals, as well as national and international publications and works. related to cystic hygroma and its importance in prenatal diagnosis.

### Data collection

Within the data collection techniques, use was made of search engines of interest such as Scielo, Elseiver, Pubmed, which offer a wide and extensive classification of valid and highly effective information so that the bibliographic source is reliable. and contribution to the study and the objective of the research, with real data and an adequate theoretical foundation.

### Information selection

In order for the information collected to be selected appropriately, the research group has designed certain selection and exclusion criteria for the analysis of the articles. Within the study, the inclusion criteria accepted all original bibliographic documents with free access and full text for download and reading. In addition, versions in Spanish, English and Portuguese were used. In addition, papers were accepted only with a period of time 2018-2022, that addressed a research topic or that were related to cystic hygroma. However, the exclusion criteria were those articles that deviated from the purpose of the study, were not relevant, had little information, or did not support its analysis. Likewise, studies that were not marked within the specific time (2018-2022), paid access articles, similar articles, plagiarism, etc. were rejected.

### Literature search technique

In order to investigate and organize the bibliographic search and avoid ambiguous results, search techniques based on key terms and Boolean operators (AND, OR, NOT) were used. The search terms were used in different search engines were. "Cystic Hygroma" "Prenatal Diagnosis" "Importance" in which other relevant articles were identified in the bibliography as shown in the table below, the keywords used for the search.

**Table 1.** Literature search strategies

<b>Use of key terms</b>	(Cystic Hygroma) AND (Prenatal Diagnosis) OR (Importance)
<b>Language</b>	Spanish, English, Portuguese
<b>Using Boolean Operators</b>	AND, OR, NOT
<b>Publications of the last 5 years</b>	2018-2022

Source: own elaboration (2023)

### Information management

Similarly, searches were made with modified variables that were related to the original study variables.

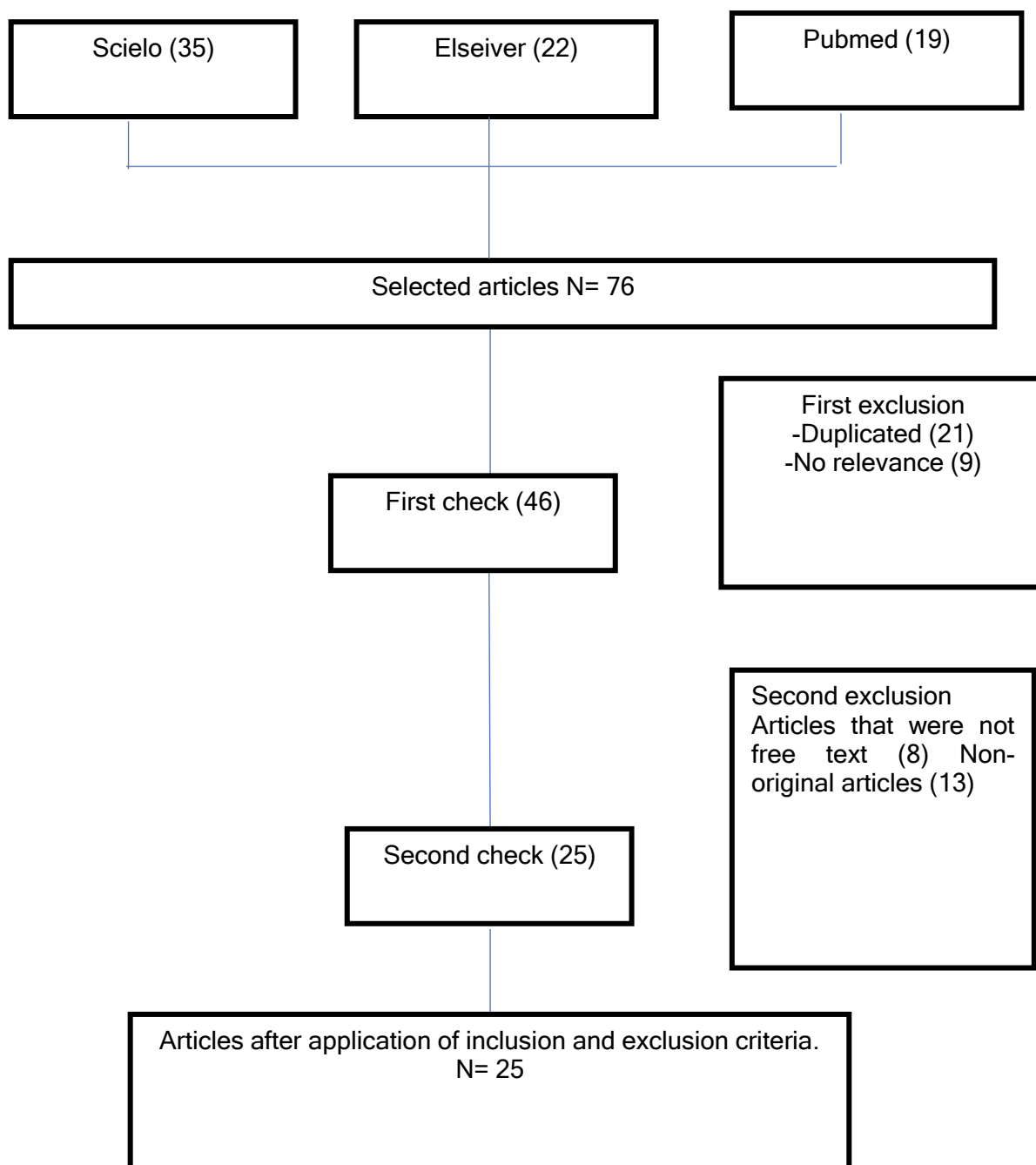
**Table 2.** Original variables and modifications made

Original variables	Variables with contradiction, implication or modification
Cystic hygroma	Definition Importance Problematic
Prenatal diagnosis	Diagnosis Treatment complications Importance

Source: own elaboration (2023)

As the articles were selected, they underwent an elimination process according to the inclusion and exclusion criteria described. Once those documents were eliminated, a descriptive table of abstracts of the articles was recorded for review in order to include or exclude them according to the aforementioned criteria. The flowchart below shows the study selection.

**Figure 1.** Selection of Studies



Source: own elaboration (2023)

## RESULTS

Table 3. Main synthesis of results

N°	Title of the article, author, year of publication	Participants	Study design	Results	Authors' interpretation	Categories
1	"Fetal cystic hygroma" Alegre P. Toko M. Cary N. (2020). p .	1 patient	Case study	The case study of a patient with cystic hygroma with facial changes and neck augmentation under deep anesthesia is analyzed.	Prenatal surveillance is important for early diagnosis through serial ultrasound, genetic testing, and fetal echocardiography, and for the formation of multidisciplinary teams for surgical treatment.	Cystic hygroma Prenatal diagnosis
2	"Cystic retronuchal hygroma as a marker of chromosomal abnormalities in the first trimester of pregnancy" Huamán M. et al. (2018). p .	459 fetuses with retronuchal cystic hygroma	Retrospective study	A total of 459 invasive procedures were analyzed, which were performed in fetuses with high risk of chromosomal malformations, 162 chromosomal abnormalities and 104 cases of hyperplasia related to cystic hygroma were detected.	Cystic hygroma is considered as an indicator of high predictive risk for chromosomal abnormalities. Identification through prenatal screening can be an indicator for the recommendation of diagnostic tests.	Cystic hygroma Prenatal diagnosis
3	"Cystic hygroma of the neck. case report" Neira J. Coronel J. Paredes D. (2020). p .	1 patient	Case study	The case presented here is the clinical presentation of a 50-year-old man with a tumor mass in the left region of the neck that had developed a year earlier, without any previous trauma, causing dyspnea due to its size and pressure on the airway, and other nearby structures.	Its diagnosis and surgical management was correct, despite its large size and the time of evolution.	Cystic hygroma Prenatal diagnosis
4	"Cervical cystic hygroma versus submandibular gland. Presentation of surgical case" (Espino S. et al. 2019. p .).	1 patient	Case study	The case of a three-year-old girl is exposed, presenting a cystic hygroma in the left cervical region, the same one that generated atrophy of the submandibular gland on that side, which received surgical treatment.	Depending on the location and structure, treatment can range from palliative treatment with sclerosing drugs to reducing the size of the tumor in order to perform surgery if possible, and in some cases surgery is the first option.	Cystic hygroma Prenatal diagnosis
5	"Cystic hygroma in a newborn of a woman with systemic lupus erythematosus" Solis C. et al (2018). p .	1 patient	Case study	The case analysis of a newborn with cystic hygroma who is the son of a 33-year-old patient with systemic lupus erythematosus is studied.	With a gynecological history, she had a previous gynecological pregnancy and an abortion at week 14 of gestation, which led her to start a fertility program with a rheumatologist and a gynecologist.	Cystic hygroma Prenatal diagnosis
6	Presentación de un caso: síndrome de Claude Bernard-Horner post resección de higroma quístico	1 patient	Case study	Cystic hygromas are congenital malformations formed by one or several fluid-filled nodes that are usually recognized in the newborn, but only become visible when the patient grows.	Although cystic hygroma is a lymphatic malformation, surgical removal of the lymphatic malformation can cause Claude Bernard Horner syndrome in both infants and adults, so this treatment is now considered advisable.	Cystic hygroma Prenatal diagnosis
7	Cystic hygroma and the importance of the prenatal diagnosis: about a case Almonacid I. et al (2020). p .	1 patient	Case study	The diagnosis of cystic hygroma. As there was no karyotype analysis, it was not possible to establish the pre-existence of any genetic abnormality. Also known as cystic lymphangioma, it is a benign vascular tumor whose prenatal diagnosis by ultrasound is essential in the evolution and prognosis of the disease.	The lack of prenatal check-ups and the absence of ultrasonographic studies that would allow us to know the characteristics of this lymphangioma could significantly affect the fatal outcome. It is a benign vascular tumor whose prenatal diagnosis by ultrasound is fundamental in the evolution and prognosis of the disease.	Cystic hygroma Prenatal diagnosis
8	"Prenatal diagnosis in Cornelia de Lange Syndrome regarding 2 cases" Taqua R. et al. (2018). p ...	2 pregnant patients	Case study, correlational	Prenatal diagnosis of the syndrome is limited to detection of major abnormalities, since the characteristic phenotype is not easily recognized.	Intrauterine growth retardation, uterine retroversion, upper extremity abnormalities of varying severity, and other cardiovascular, gastrointestinal, and urologic abnormalities that affect fetal prognosis often occur.	Cystic hygroma Prenatal diagnosis
9	Prenatal ultrasound diagnosis and neonatal outcomes of pulmonary cystic adenomatoid malformation	17 prenatal cases	Retrospective study	Computed tomography is the technique of choice to confirm the resolution of lesions after birth.	The fetus with cystic hygroma may be associated with other anomalies such as Turner syndrome, Down syndrome, trisomy 18, trisomy 13, Noonan syndrome,	Cystic hygroma Prenatal diagnosis
10	Prenatal diagnosis of congenital malformations and chromosomal alterations: result of the CIMAF experience - Hospital Dr. Sótero Del Rio	404 patients with suspected congenital malformations	Retrospective and descriptive study	The most frequent malformations were cardiovascular, central nervous system, hydrops, extremities, abdomen and genitourinary	Biopsy correlation is sometimes necessary for accurate diagnosis of lesion occurring in unusual locations.	Cystic hygroma Prenatal diagnosis
11	Birth defects diagnosed by two-dimensional ultrasonography	967 pregnant women with a confirmed diagnosis of birth defects	Descriptive study	The most frequent results by ultrasound were alterations of the central nervous system, genitourinary and cardiovascular systems.	In most large series of prenatally diagnosed second-trimester fetuses, this still accounts for more than 50% of chromosomal abnormalities.	Cystic hygroma Prenatal diagnosis
12	Prognosis of fetal nuchal translucency $\geq 5.5$ mm in Lima, Peru	10,340 consecutive fetuses between 11 and 13 weeks	Observational retrospective study	The frequency of a chromosomal abnormality approaches 50%.	Classification based on ultrasound appearance is artificial and does not represent distinct abnormalities, but rather is a continuum of the lymphatic obstruction sequence	Cystic hygroma Prenatal diagnosis
13	Obstetric complications related to antiretroviral therapy in HIV-infected pregnant women	141 HIV-infected pregnant women	retrospective study	They were not related to plasma viral load and no increase in the rate of gestational interruptions, malformations or gestational diabetes was found.	If a hygroma is identified in the first trimester, the following treatment is suggested.	Cystic hygroma Prenatal diagnosis
14	Prevalence of fetal congenital malformations detected by ultrasound	58 pregnant patients	Observational, descriptive, retrospective study	Cardiac malformations were the most frequent, followed by those of the central nervous system and abdomen.	If the hygromas resolve before 20 weeks, it can be said that these babies will probably be morphologically normal.	Cystic hygroma Prenatal diagnosis
15	Prevalence of congenital malformations in children of mothers older than 34 years and adolescents	15636 births	Retrospective study	An increased risk of fetal chromosomal abnormalities in cases of fetal cystic hygroma detected in the first trimester	Increased frequency of autosomal abnormalities in the first trimester may lead to increased first-trimester miscarriages	Cystic hygroma Prenatal diagnosis
16	Cystic Lymphangioma Revision	1 patient	Case study	Ultrasound is the test of first choice in pediatric diagnosis due to its safety and provides important information in the study of cystic hygroma.	If cystic hygromas are not adequately detected, complications can arise.	Cystic hygroma Prenatal diagnosis
17	Imaging diagnosis of occipital encephalocele. About a case.	1 patient	Case study	During the course of the infection, the cystic hygroma enlarges and becomes hot, red, and tender.	The infection can affect the entire cystic hygroma or some of its cysts.	Cystic hygroma Prenatal diagnosis
18	Cystic lymphangioma. Case report in Guyana	1 patient	Case study	Prenatal ultrasound performed in the first and second trimester of pregnancy by trained personnel is an economical and non-invasive diagnosis that allows early diagnosis and appropriate conduct.	Sometimes the cystic hygroma develops into an abscess, which must be drained to improve symptoms.	Cystic hygroma Prenatal diagnosis
19	Inguinal cystic lymphangioma in a patient	1 patient	Case study	Cystic lymphangioma, being a rare pathology, its diagnosis must be suspected.	Spontaneous rupture, on the fourth day after birth, of a giant cystic hygroma of the neck, which required urgent surgical intervention.	Cystic hygroma Prenatal diagnosis
20	Morbidly adherent placenta associated with congenital malformations: case report.	1 pregnant patient	Case study	Trisomy 13 is a genetic condition that, due to the multiple associated malformations, is considered incompatible with life.	Other complications are respiratory difficulties and dysphagia, especially in cystic hygroma of the neck and oral cavity.	Cystic hygroma Prenatal diagnosis

Source: own elaboration (2023)

## DISCUSSION

As has been studied in the medical literature, cystic hygromas can manifest in any part of the body. Inside the study of Alegre P. Toko M. Cary N. (2020). p., the usual locations are the cervicofacial regions (especially the posterior cervical triangle), the axilla, the mediastinum, the groin, and under the tongue.

In addition Huamán M. et al (2018). p., "details that occasionally, these malformations occur in the liver, spleen, kidney and intestine".

However, other infrequent locations have been observed within the study by Neira J. Coronel J. Paredes D. (2020). p., especially on the extremities, chest wall, cheek, lumbar region, suprasternal area, and over the shoulder or deltoid. The authors describe that, although they are usually isolated and unique on these rare occasions, cystic hygromas have been observed at multiple locations on the body.

Under these arguments, it suggests that cystic hygroma should always be considered first in the preliminary differential diagnosis of cystic lesions starting at birth and in the mentioned location. Argument accepted by Espino S. et al. (2019). p., who in his study mentions "that more than 60% of cystic hygromas appear at birth and up to 90% manifest before two years of age."

However, the appearance of cystic hygroma in adults has hardly been described in the literature. Some case reports describe the post-traumatic (acquired cystic hygroma) occurrence of cystic hygroma in previously normal adults. These cases could represent the latent variety of cystic hygromas that can appear at any age, and trauma could be a chance event in such cases.

"Now, within the diagnosis, in the clinical examination, these lesions appear soft, compressible, non-sensitive, transluminous and without any murmur" Solís C. et al (2018). p. On the other hand, Barrientos S. et al. (2017). p., details "that an ultrasound of the lesion usually shows a multicystic lesion with internal septations and no blood flow is detected on color Doppler ultrasound".

Likewise Noia G. et al (2013). p. ensures that other modalities such as CT (Computerized Tomography) and MRI (Magnetic Resonance Imaging) can be used to better delineate the lesion. The difference is that CT shows a multicystic, homogeneous, non-invasive density with low attenuation.

In other words, these modalities are often useful in determining the extent of the lesion and its association with nerves and vessels, and are particularly useful when contemplating surgical management of the lesion. These cysts may produce a milky, serous, serosanguineous, or straw-colored fluid when aspirated with a large-gauge needle.

However, prenatal diagnosis of cystic hygroma by ultrasound is well documented in the literature and has been the most widely used in different studies. According to Taqua R. et al. (2018). p., the characteristic sonographic appearance on prenatal ultrasound is that of a thin-walled multiseptate cystic mass; occasionally, the cystic mass may have a more complex echo texture with both cystic and solid components.

In addition Gallardo A. et al (2018). p., mentions that the fetus with cystic hygroma may be associated with other anomalies in approximately 62% of cases. Associated anomalies are Turner syndrome, Down syndrome, trisomy 18, trisomy 13, Noonan syndrome, etc.

Under the research line of Vargas P. et al (2020). p., "biopsy correlation is sometimes necessary for accurate diagnosis of lesion that occurs in unusual locations such as laryngeal, intraoral, and orbital lymphangiomas."

Prenatal diagnosis of cystic hygromas is a difficult counseling task. They may be an isolated finding or be associated with chromosomal, structural, and genetic syndromes. As detailed by Núñez A. et al (2022). p., "At one time, these malformations were thought to be pathonomics of Turner syndrome. In most large series of second-trimester fetuses diagnosed prenatally, this still represents more than 50% of chromosomal abnormalities."

In this series, the frequency of a chromosomal abnormality approaches 50%. Neither the anatomical appearance nor the presence of septations seem to be of value in predicting a chromosome aberration. It is possible that the classification based on the ultrasound appearance is artificial and does not represent different anomalies, but rather is a continuum of the lymphatic obstruction sequence (Diez G. Bazán M. 2019. p.).

With the exception of a few case reports, hydrops has been a poor prognostic finding. In a study by Calvo M. et al (2022). p., four fetuses with diffuse hydrops resolved and had good neonatal outcomes, suggesting that if a hygroma is

identified in the first trimester, the following treatment is suggested. Which should be offered a karyotype by CVS or amniocentesis. If the chromosomes are normal, a detailed ultrasound and counseling should be performed.

In addition, ultrasonographic surveillance should be performed using serial scans to identify resolution of hygromas. If the hygromas resolve before 20 weeks, it can be said that these babies will probably be morphologically normal. It is important to note that there is no long-term follow-up of these fetuses, as well as fetuses with normal chromosomes and persistent hygromas Rattia F. Gelvis M. (2022).

"However, authors have shown a higher risk of fetal chromosomal abnormalities in cases of fetal cystic hygroma detected in the first trimester, specifically autosomal aneuploidy at frequencies systematically higher than those associated with cystic hygroma in the second trimester" Nazer J. Cifuentes L. (2013). p.

The increased frequency of autosomal abnormalities in the first trimester may lead to increased first-trimester miscarriages, resulting in cases of second-trimester cystic hygroma showing higher relative frequencies of mosaic and nonmosaic monosomy X (Franco D. et al. 2022).

However, if cystic hygromas are not adequately detected, complications can arise. According to Borrego L. Arteaga J Moliineda K. (2019), "these lesions can become infected at any time due to the seeding of microorganisms from a secondary source of infection (respiratory tract infections), although they can also be infected primarily."

## CONCLUSIONS

Cystic hygroma is a multiloculated cyst lined by endothelial cells that occurs as a result of a lymphatic malformation. Most affect the jugular lymphatic sacs and present in the posterior region of the neck. Other common locations are the axillary, mediastinal, inguinal and retroperitoneal regions, these cystic lesions are present at birth. Cystic hygromas are soft cystic masses that can distort surrounding structure, including the airways. A large cystic mass in the fetal neck can pose a significant threat to the airway at birth.

Prenatal ultrasonography and fetal magnetic resonance imaging (MRI) studies may better demonstrate the extent of disease along with its airway mass effect. If present, careful timing of the surgical intervention, intrauterine treatment procedure (EXIT), at the time of delivery can be life-saving, although this is more likely with solid tumors such as teratomas. Cystic hygromas are prone to infection and bleeding within the mass. MRI is useful in delineating the extent of lymphatic channels.

When a prenatal diagnosis of cystic hygroma is made by transvaginal or transabdominal ultrasound, karyotyping should be recommended in all cases. The ultrasonographic examination for the diagnosis of fetal hydrops should help in the management of the pregnancy and is useful in the counseling of future pregnancies. In the fetus with associated chromosomal abnormality or hydrops, the chances of survival are low, so the option of terminating the pregnancy should be offered before fetal viability.

The process is detailed in the research by Segundo R. Cruz C. Morales C. (2019). p., who mentions that "during the course of the infection, the cystic hygroma increases in size and becomes hot, red and tender. The patient may become feverish. The infection can affect the entire cystic hygroma or some of its cysts.

Also, during active infection, it may not remain translucent. Sometimes the cystic hygroma develops into an abscess, which must be drained to improve symptoms. Treatment is conservative with antibiotics, antipyretics and analgesics. We observed that, in some cases, the size of the cystic hygroma after infection is markedly reduced (Sanz M. et al 2018. p.)

The other most frequently reported and observed complication is spontaneous bleeding into the cyst. In this case, the cysts tighten and harden. When aspirated, they produce a hemorrhagic fluid. Spontaneous bleeding in scrotal lymphangioma may have to be treated surgically to avoid testicular ischemia. Sandoval-Martínez D. et al (2020). p., reported spontaneous rupture, on the fourth day after birth, of a giant cystic hygroma of the neck, which required urgent surgical intervention.

Other complications are respiratory difficulties and dysphagia, especially in cystic hygroma of the neck and oral cavity. Sometimes, cystic hygroma of the neck and oral cavity occur simultaneously in the same patient, creating a difficult situation for the treatment of respiratory distress and dysphagia. Lymphatic discharge from the sinus, resulting from infection or trauma, is another rare complication (Almonacid I. et al 2020. p.).

It is important to emphasize the importance of prenatal control as a diagnostic method in the early identification of complications, through continuous education to the mother to attend them.

## REFERENCES

- Andrade A, Chavez T, Cruz C, Daniela Alegre Andrade N, Hospital Obrero MN, Nacional de Salud C, et al. Casos Clínicos Higroma quístico fetal Fetal cystic hygroma. *Period Semest.* 2019;42(2). Disponible en: [http://ve.scielo.org/scielo.php?script=sci\\_arttext&pid=S0048-77322003000300005](http://ve.scielo.org/scielo.php?script=sci_arttext&pid=S0048-77322003000300005)
- Alegre Andrade P, Toko Chavez M, Cary Cruz ND. Higroma quístico fetal. *Gac Medica Boliv.* 1 de octubre de 2020;42(2):159-62. Disponible en: [https://rcoe.es/articulo/79/higroma-quistico-cervical-versus-glandula-submaxilar-presentacin-de-caso-quirrgico#:~:text=INTRODUCCI%C3%93N,El%20higroma%20qu%C3%ADstico%20\(HQ\)%20fetal%20es%20una%20malformaci%C3%B3n%20cong%C3%A9nita%20benigna,multilocular%20de%20tama%C3%B1o%20variable.](https://rcoe.es/articulo/79/higroma-quistico-cervical-versus-glandula-submaxilar-presentacin-de-caso-quirrgico#:~:text=INTRODUCCI%C3%93N,El%20higroma%20qu%C3%ADstico%20(HQ)%20fetal%20es%20una%20malformaci%C3%B3n%20cong%C3%A9nita%20benigna,multilocular%20de%20tama%C3%B1o%20variable.)
- Almonacid I, Zuleta P, Neri C, Zannin A, Garzón M, Dorado J, et al. Higroma quístico y la importancia de su diagnóstico prenatal: a propósito de un caso. *BAG J Basic Appl Genet.* diciembre de 2020;31(2):39-44. Disponible en: [http://www.scielo.org.ar/scielo.php?script=sci\\_arttext&pid=S1852-62332020000300039#:~:text=El%20higroma%20qu%C3%ADstico%2C%20tambi%C3%A9n%20conocido,et%20al.%2C%202019.](http://www.scielo.org.ar/scielo.php?script=sci_arttext&pid=S1852-62332020000300039#:~:text=El%20higroma%20qu%C3%ADstico%2C%20tambi%C3%A9n%20conocido,et%20al.%2C%202019.)
- Barrientos SA, Senaedy Borjas M, Lagos KA, Varela D. Presentación de un caso: síndrome de Claude Bernard-Horner post resección de higroma quístico. *Rev Cient Cienc Medica.* 2017;20(2). Disponible en: <https://netmd.org/pediatria/ pediatria- articulos/ presentacion-de-un-caso-sindrome-de-claude-bernard-horner-post-reseccion-de-higroma-quistico>
- Borrego LE, Arteaga JC, Mollineda KM, Guerra EC. Diagnóstico imagenológico de encefalocele occipital. A propósito de un caso. *Dilemas Contemp Educ Política Valores [Internet].* 1 de noviembre de 2019 [citado 16 de mayo de 2022]; Disponible en: <https://www.dilemascontemporaneoseducacionpoliticaayvalores.com/index.php/dilemas/article/view/1314>
- Calvo Alemán M, de la Calle M, Montes Ramírez ML, Escosa García L, Elorza MD, González García J, et al. Complicaciones obstétricas relacionadas con la terapia antirretroviral en gestantes infectadas por el VIH. *Clínica E Investig En Ginecol Obstet.* 1 de enero de 2022;49(1):100713. Disponible en: <https://www.sciencedirect.com/science/article/abs/pii/S0210573X21000721>
- Diez Chang G, Bazán Lossio de Diez MG. Pronóstico de la translucencia nucal fetal  $\geq 5,5$  mm en Lima, Perú. *Rev Peru Ginecol Obstet.* octubre de 2019;65(4):455-9. Disponible en: [http://www.scielo.org.pe/scielo.php?pid=S2304-51322019000400007&script=sci\\_arttext](http://www.scielo.org.pe/scielo.php?pid=S2304-51322019000400007&script=sci_arttext)
- Espino Otero S, Manuel Pose Rodríguez J, de la Paz Otero Casal M, Jorge González Manso B, Jiménez Gómez L, Bucal C, et al. Higroma quístico cervical versus glándula submaxilar. Presentación de caso quirúrgico. *RCOE.* 2019;24(2):2019. Disponible en: <https://rcoe.es/articulos/79-higroma-quistico-cervical-versus-glandula-submaxilar-presentacin-de-caso-quirrgico.pdf>
- Franco DCMB, Calvo DJRYC, Lorente DMC, Lacámara DLS, Muñoz DDI. Revisión del linfangioma quístico. *Seram [Internet].* 18 de mayo de 2021 [citado 16 de mayo de 2022];1(1). Disponible en: <https://piper.espacio-seram.com/index.php/seram/article/view/4712>
- Gallardo A. M, Álvarez de la Rosa R. M, De Luis E. JF, Mendoza R. L, Padilla P. AI, Troyano L. J, et al. Diagnóstico ecográfico prenatal y resultados neonatales de la malformación adenomatoidea quística pulmonar. *Rev Chil Pediatría.* abril de 2018;89(2):224-30. Disponible en: [https://www.scielo.cl/scielo.php?script=sci\\_arttext&pid=S0370-41062018000200224](https://www.scielo.cl/scielo.php?script=sci_arttext&pid=S0370-41062018000200224)
- Guevara Ríos E, Carranza-Asmat C, Meza-Santibañez L, Ayala-Peralta F, Arango-Ochante P, Espinola-Sánchez M, et al. Caracterización epidemiológica, anticoncepción y bienestar psicológico en mujeres a dos años post aborto terapéutico. *Rev Peru Investig Materno Perinat.* 2021;10(2). Disponible en: <https://investigacionmaternoperinatal.inmp.gob.pe/index.php/rpinmp/article/view/233>
- Huamán Guerrero M, Sosa Olavarría A, Huamán J M, Díaz K A. Higroma quístico retrorucal como marcador de anomalías cromosómicas en el primer trimestre de la gestación. *Rev Peru Ginecol Obstet.* 28 de septiembre de 2018;64(3):331-5. Disponible en: [http://www.scielo.org.pe/scielo.php?script=sci\\_arttext&pid=S2304-51322018000300003#:~:text=Concluyendo%2C%20el%20higroma%20qu%C3%ADstico%20retrorucal,cariotipo%20u%20otras%20pruebas%20gen%C3%A9ticas.](http://www.scielo.org.pe/scielo.php?script=sci_arttext&pid=S2304-51322018000300003#:~:text=Concluyendo%2C%20el%20higroma%20qu%C3%ADstico%20retrorucal,cariotipo%20u%20otras%20pruebas%20gen%C3%A9ticas.)
- Nazer Herrera J, Cifuentes Ovalle L. Prevalencia de malformaciones congénitas en hijos de madres mayores de 34 años y adolescentes: Hospital Clínico de la Universidad de Chile, 2002-2011. *Rev Chil Obstet Ginecol.* 2013;78(4):298-303. Disponible en: <https://pesquisa.bvsalud.org/gim/resource/fr/lil-692207>
- Neira Borja JE, Coronel Rulova JM, Paredes Calahorrano DR, Neira Verduga MDF. HIGROMA QUÍSTICO DEL CUELLO. INFORME DE UN CASO. *Medicina (Mex).* 22 de agosto de 2018;19(3):176-9. Disponible en: [http://scielo.sld.cu/scielo.php?script=sci\\_arttext&pid=S1028-99332018000400835#:~:text=Se%20present%C3%B3%20el%20caso%20de,de%20la%20nuca%20del%20feto.](http://scielo.sld.cu/scielo.php?script=sci_arttext&pid=S1028-99332018000400835#:~:text=Se%20present%C3%B3%20el%20caso%20de,de%20la%20nuca%20del%20feto.)
- Noia G, Pellegrino M, Masini L, Visconti D, Manzoni C, Chiaradia G, et al. Fetal cystic hygroma: the importance of natural history. *Eur J Obstet Gynecol Reprod Biol.* 1 de octubre de 2013;170(2):407-13. Disponible en: <https://pubmed.ncbi.nlm.nih.gov/23988219/>
- Núñez Copo AC, Gómez Pérez HP, Arguelles Arza M, Frómata Montoya CI, Núñez Copo AC, Gómez Pérez HP, et al. Defectos congénitos diagnosticados por ultrasonografía bidimensional. *Rev Cuba Med Gen Integral [Internet].* marzo de 2021 [citado 16 de mayo de 2022];37(1). Disponible en: [http://scielo.sld.cu/scielo.php?script=sci\\_abstract&pid=S0864-21252021000100004&lng=es&nrm=iso&tlng=es](http://scielo.sld.cu/scielo.php?script=sci_abstract&pid=S0864-21252021000100004&lng=es&nrm=iso&tlng=es)
- Mukakala AK, Banza MI, Musapudi EM, Lubosha NA, Kasanga TK, Nafatalewa DK, et al. Cystic hygroma of the neck in a young adult: About a case and literature review. *Vol. 36, Pan African Medical Journal.* 2020. Disponible en: <https://pubmed.ncbi.nlm.nih.gov/32774629/>
- Pan M, Liu YN, Xu LL, Li DZ. First-trimester cystic hygroma and neurodevelopmental disorders: The association to remember. *Taiwan J Obstet Gynecol.* 2020;59(6). Disponible en: <https://pubmed.ncbi.nlm.nih.gov/33218422/>
- Rattia FMF, Gelvis MC. Prevalencia de malformaciones congénitas fetales detectadas mediante ultrasonido. *Rev Científica CMDLT [Internet].* 2021 [citado 16 de mayo de 2022];15(1). Disponible en: <https://www.cmdltditorial.org/index.php/CMDLT/article/view/30>
- Romero Caballero D, Atobe O. Edwards syndrome or trisomy 18: a case report. *Nac.* 2016;7(2). Disponible en: <https://www.hilarispublisher.com/open-access/a-case-report-on-edward-syndrome.pdf>
- Sanz MBR, Pérez AH, Hernández NM, Blázquez LMU. Linfangioma quístico inguinal en paciente adulta: Una patología y localización inusual. *Rev Esp Investig Quirúrgicas.* 2018;21(3):101-5. Disponible en: <https://academic.oup.com/jscr/article/2020/7/rjaa179/5870354>
- Sandoval-Martínez DK, Gutiérrez-Sánchez LÁ, Jaimes-Sanabria MZ, Sandoval-Martínez DK, Gutiérrez-Sánchez LÁ, Jaimes-Sanabria MZ. Placenta mórbidamente adherente asociada a malformaciones congénitas: reporte de caso. *Rev Chil Obstet Ginecol.* agosto de 2020;85(4):392-9. Disponible en: [https://www.scielo.cl/scielo.php?script=sci\\_arttext&pid=S0717-75262020000400392](https://www.scielo.cl/scielo.php?script=sci_arttext&pid=S0717-75262020000400392)
- Segundo RC, Cruz CA, Morales CDY. Cystic lymphangioma. Case report in Guyana. *Rev Inf Científica.* 2018;97(4):835-41.



- Solis Cartas UI, Johana Calvopina Bejarano SI, Prada Hernandez III D, Molinero Rodriguez CI, Alexis Gomez Morejon J V. Higroma quístico en recién nacido de mujer con lupus eritematoso sistémico. *Rev Cuba Reumatol.* 2018;20(1):1-4. Disponible en: [http://scielo.sld.cu/scielo.php?script=sci\\_arttext&pid=S1817-59962018000100012](http://scielo.sld.cu/scielo.php?script=sci_arttext&pid=S1817-59962018000100012)
- Taqua R. B, Sabonet M. L, Perez-Moneo P. P, Perez E. ML, Sanchís A, Reyes Balanzá C. M, et al. Diagnostico prenatal en Síndrome de Cornelia de Lange a propósito de 2 casos. *Rev Chil Obstet Ginecol.* 2018;83(1):93-8. Disponible en: [https://www.scielo.cl/scielo.php?script=sci\\_arttext&pid=S0717-75262018000100093#:~:text=Se%20caracteriza%20por%20un%20fenotipo,mismo%20no%20son%20f%C3%A1cilmente%20detectables](https://www.scielo.cl/scielo.php?script=sci_arttext&pid=S0717-75262018000100093#:~:text=Se%20caracteriza%20por%20un%20fenotipo,mismo%20no%20son%20f%C3%A1cilmente%20detectables).
- Torres-Palomino G, Juárez-Domínguez G, Guerrero-Hernández M, Méndez-Sánchez L. Obstrucción de la vía aérea por higroma quístico en un recién nacido. *Bol Med Hosp Infant Mex.* 3 de julio de 2014;71(4):233-7. Disponible en: [https://www.scielo.org.mx/scielo.php?script=sci\\_arttext&pid=S1665-11462014000400007#:~:text=El%20higroma%20qu%C3%ADstico%20\(HQ\)%20fetal,multilocular%20y%20de%20tama%C3%B1o%20variable](https://www.scielo.org.mx/scielo.php?script=sci_arttext&pid=S1665-11462014000400007#:~:text=El%20higroma%20qu%C3%ADstico%20(HQ)%20fetal,multilocular%20y%20de%20tama%C3%B1o%20variable).
- Utomo MT, Harahap A, Etika R. Massive cystic hygroma of the neck with respiratory distress in newborn. *J Pediatr Surg Case Rep.* 2021;71. Disponible en: <https://www.sciencedirect.com/science/article/pii/S2213576621001664>
- Vargas P, Mergudich T, Martinovic C, Córdova V, Valdés R, Luna D, et al. Diagnóstico prenatal de malformaciones congénitas y alteraciones cromosómicas: resultado de la experiencia CIMAF - Hospital Dr. Sótero Del Río. *Rev Chil Obstet Ginecol.* agosto de 2020;85(4):358-65. Disponible en: [https://www.scielo.cl/scielo.php?pid=S0717-75262020000400358&script=sci\\_abstract#:~:text=El%20diagn%C3%B3stico%20prenatal%20de%20anomal%C3%ADas,para%20un%20%C3%B3ptimo%20manejo%20perinatal](https://www.scielo.cl/scielo.php?pid=S0717-75262020000400358&script=sci_abstract#:~:text=El%20diagn%C3%B3stico%20prenatal%20de%20anomal%C3%ADas,para%20un%20%C3%B3ptimo%20manejo%20perinatal).
- Yakıştıran B, Altınboğa O, Canpolat E, Çakar EŞ, Çelen Ş, Çağlar AT, et al. Analysis of cystic hygroma diagnosed in the first trimester: Single-center experience. *J Turk Ger Gynecol Assoc.* 2020;21(2). Disponible en: <https://pubmed.ncbi.nlm.nih.gov/31298510/>

#### Contribution of each author to the manuscript:

Task	% of contribution of each author				
	A1	A2	A3	A4	A5
A. theoretical and conceptual foundations and problematization:	20%	20%	20%	20%	20%
B. data research and statistical analysis:	20%	20%	20%	20%	20%
C. elaboration of figures and tables:	20%	20%	20%	20%	20%
D. drafting, reviewing and writing of the text:	20%	20%	20%	20%	20%
E. selection of bibliographical references	20%	20%	20%	20%	20%
F. Other (please indicate)	-	-	-	-	-

#### Indication of conflict of interest:

There is no conflict of interest

#### Source of funding

There is no source of funding

#### Acknowledgments

There is no acknowledgments