

Recent advances in interventional cardiology for coronary artery disease: a systematic literature review

Avanços recentes em cardiologia intervencionista para doença arterial coronariana: uma revisão sistemática da literatura

Avances recientes en cardiología intervencionista para la enfermedad arterial coronaria: una revisión sistemática de la literatura

Ana Paula Coronel Mite<https://orcid.org/0009-0005-2435-5492> Graduate researcher. Physician, Universidad Católica Santiago de Guayaquil, Ecuador
anapaula.cm@hotmail.es (correspondence)**Rafael Andres Mosquera-Ceprian**<https://orcid.org/0009-0002-9626-3173> Graduate researcher. Physician, Universidad Católica Santiago de Guayaquil, Ecuador
rmosquera1999@gmail.com**Christian Abraham Orellana Franco**<https://orcid.org/0009-0007-9350-7191> Graduate researcher. Physician, Ministerio de Salud Pública del Ecuador
cristianorellanafranco1993@hotmail.com**Gabriela Samantha Meza Pacheco**<https://orcid.org/0009-0007-9588-5807> Graduate researcher. Physician, Ministerio de Salud Pública del Ecuador
gabrielamezapacheco96@gmail.com**José Mauricio Paredes Torres**<https://orcid.org/0009-0004-8536-1004> Graduate researcher. Physician, ONCOSALUD, Ecuador
franklin.cashabamba@udla.edu.ec**ARTICLE HISTORY****Received:** 24-01-2024**Revised Version:** 29-03-2024**Accepted:** 04-05-2024**Published:** 14-05-2024**Copyright:** © 2024 by the authors**License:** CC BY-NC-ND 4.0**Manuscript type:** Article**ARTICLE INFORMATION****Science-Metrix Classification (Domain):**

Health Sciences

Main topic:

Interventional cardiology and coronary disease

Main practical implications:

The article highlights advances in the treatment of CAD, including improved diagnostic techniques, less invasive interventional procedures, emerging drug treatments, and the integration of cutting-edge surveillance technologies. These advances offer early detection, personalized treatment and precise monitoring, potentially reducing risks and improving outcomes for patients with CAD.

Originality/value:

This article is original in the sense of incorporating cutting-edge, recent and useful information for the construction of new research agendas. Especially in developing countries, the insights presented here can help the formulation of policy initiatives in the public or private context to combat coronary artery disease.

ABSTRACT

Recent advancements and innovations in interventional cardiology have already revolutionized coronary artery disease (CAD) treatment and management. Interventional cardiology is a new hope for CAD patients because its evolution has improved disease symptoms. We aimed to explore the integration of diagnostic, therapeutic, and risk management innovations against CAD. In diagnostic advancements, we aimed to discuss the evolution of imaging techniques such as MRI, echocardiography, positron emission tomography (PET), and coronary computed tomography angiography (CCTA), focusing on their unique benefits in the early detection and assessment of CAD. Interventional techniques, notably percutaneous coronary intervention (PCI) innovations, have evolved, incorporating bioresorbable vascular scaffolds, drug-eluting stents, and advanced imaging technologies to enhance procedural success and patient outcomes. Moreover, post-PCI care advancements, including newer antiplatelet agents and PCSK9 inhibitors, have contributed to more personalized and effective CAD management strategies. This paper will also discuss significant strides made in interventional cardiology, underscoring a future where integrated approaches continue to advance patient care in CAD.

Keywords: Interventional cardiology, coronary artery disease, literature review.**RESUMO**

Os recentes avanços e inovações na cardiologia intervencionista já revolucionaram o tratamento e o gerenciamento da doença arterial coronariana (DAC). A cardiologia intervencionista é uma nova esperança para os pacientes com DAC porque sua evolução melhorou os sintomas da doença. Nosso objetivo foi explorar a integração de inovações diagnósticas, terapêuticas e de gerenciamento de risco contra a DAC. Em relação aos avanços diagnósticos, pretendemos discutir a evolução das técnicas de imagem, como ressonância magnética, ecocardiografia, tomografia por emissão de pósitrons (PET) e angiotomografia computadorizada coronariana (ATCC), com foco em seus benefícios exclusivos na detecção precoce e avaliação da DAC. As técnicas intervencionistas, principalmente as inovações da intervenção coronária percutânea (ICP), evoluíram, incorporando andaimes vasculares biorreabsorvíveis, stents com eluição de fármacos e tecnologias avançadas de imagem para melhorar o sucesso do procedimento e os resultados dos pacientes. Além disso, os avanços nos cuidados pós-ICP, incluindo novos agentes antiplaquetários e inibidores de PCSK9, contribuíram para estratégias de gerenciamento de DAC mais personalizadas e eficazes. Este artigo também discutirá os avanços significativos feitos na cardiologia intervencionista, destacando um futuro em que as abordagens integradas continuarão a avançar no atendimento ao paciente com DAC.

Palavras-chave: Cardiologia intervencionista, doença arterial coronariana, revisão da literatura.**RESUMEN**

Los recientes avances e innovaciones en cardiología intervencionista ya han revolucionado el tratamiento y la gestión de la enfermedad arterial coronaria (EAC). La cardiología intervencionista es una nueva esperanza para los pacientes con EAC porque su evolución ha mejorado los síntomas de la enfermedad. Nuestro objetivo fue explorar la integración de las innovaciones diagnósticas, terapéuticas y de gestión de riesgos contra la EAC. En cuanto a los avances diagnósticos, nos propusimos analizar la evolución de técnicas de imagen como la resonancia magnética, la ecocardiografía, la tomografía por emisión de positrones (PET) y la angiografía coronaria por tomografía computarizada (ACTC), centrándonos en sus ventajas únicas en la detección y evaluación precoces de la EAC. Las técnicas intervencionistas, en particular las innovaciones de la intervención coronaria percutánea (ICP), han evolucionado con la incorporación de armazones vasculares biorreabsorbibles, stents liberadores de fármacos y tecnologías de imagen avanzadas para mejorar el éxito de la intervención y los resultados en los pacientes. Además, los avances en los cuidados posteriores a la ICP, incluidos los nuevos antiagregantes plaquetarios e inhibidores de la PCSK9, han contribuido a unas estrategias de tratamiento de la EAC más personalizadas y eficaces. En este artículo también se analizarán los importantes avances logrados en cardiología intervencionista, lo que pone de relieve un futuro en el que los enfoques integrados seguirán impulsando la atención al paciente con EAC.

Palabras clave: Cardiología intervencionista, enfermedad arterial coronaria, revisión sistemática.

INTRODUCTION

Coronary Artery Disease, also known as CAD, develops with an accumulation of plaque within artery walls, which are responsible for supplying blood to the heart, known as the coronary arteries. This plaque primarily consists of deposits of cholesterol. As plaque accumulates, it narrows the arterial passages (atherosclerosis), restricting blood flow to the heart over time. The most common symptom of CAD is angina, characterized by chest pain or discomfort due to narrowed arteries hindering blood flow to the heart muscle and other body tissues. Additionally, a heart attack may serve as the initial indicator of CAD, with symptoms including chest pain, weakness, nausea, sweating, and pain in the arms or shoulder. CAD weakens the heart muscle over time and ultimately leads to heart failure, a severe condition impairing the heart's ability to pump blood effectively (CDC, 2021).

Coronary artery disease (CAD) is a very common heart disease across the United States _about 18 million people are suffering from it, and alternately referred to as coronary heart disease or ischemic heart disease (Cleveland Clinic, n.d).. Coronary heart disease accounts for the highest heart disease incidences, claiming the lives of 375,476 individuals in 2021 (Heart Disease Facts CDC., 2023). Approximately 5% of adults aged 20 and above grapple with CAD. Notably, in 2021, nearly 20% of CAD-related deaths occurred in adults under 65 years of age (Heart Disease Facts CDC., 2023).

Its important to note that CAD is primarily caused by atherosclerosis and is partly a genetic disease (Heart Disease Facts CDC., 2023). Atherosclerosis is the gradual buildup of plaque in arteries throughout the body. Plaque, along with cholesterol, waste products, calcium, and fibrin, accumulates along artery walls, causing them to narrow and stiffen. This restricts blood flow, leading to insufficient oxygen and nutrients reaching the heart muscle, resulting in myocardial ischemia and symptoms like angina or heart attack. Additionally, individuals with plaque buildup in their coronary arteries often exhibit similar buildup in other parts of the body, potentially leading to conditions such as carotid artery disease and peripheral artery disease (PAD) (Cleveland Clinic, n.d).

In this article, through a systematic review of the recent state-of-the-art literature, we will examine the main interventions recommended by specialized research in treating coronary artery disease. The relevance of this review lies mainly in analyzing and considering very recent literature, which allows the scientific community, mostly in developing countries, access to state-of-the-art evidence in a systematized and analytical way to make better informed decisions regarding therapeutics and clinical treatments.

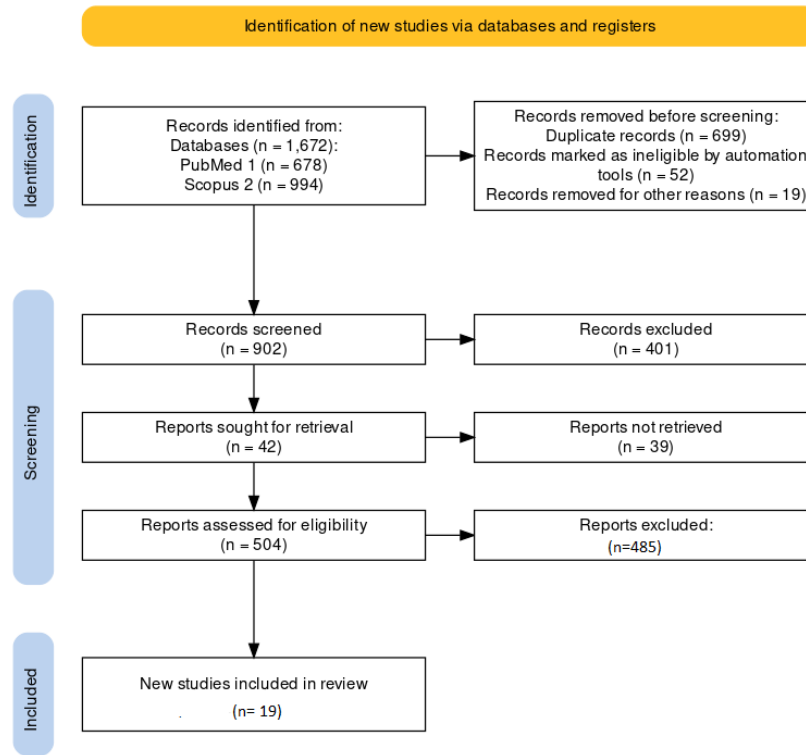
METHODS

For our topic, *Recent Advances in Interventional Cardiology for Coronary Artery Disease*, our methodology involved a complete search of scientific databases, including Scopus and Web of Science. The inclusion criteria were peer-reviewed articles published in English focusing on the latest developments in diagnostic and interventional techniques for coronary artery disease (CAD) and advancements in post-PCI care and management strategies. While screening, we screened titles and abstracts for relevance, followed by a full-text review. It was ensured that the inclusion of the most pertinent and high-quality studies was compiled. Our methodology approach ensured a thorough exploration of the subject matter, emphasizing the integration of diagnostic, therapeutic, and risk management innovations in improving outcomes for CAD patients only.

Keywords included:

Interventional Cardiology, Coronary Artery Disease (CAD), Percutaneous Coronary Intervention (PCI), Diagnostic Imaging Techniques, Bioresorbable Vascular Scaffolds, Drug-Eluting Stents, Post-PCI Care, Antiplatelet Agents, PCSK9 Inhibitors, Personalized Medicine, Myocardial Perfusion Imaging, Coronary Computed Tomography Angiography (CCTA), Magnetic Resonance Imaging (MRI), Echocardiography, Positron Emission Tomography (PET), Risk Management Strategies, Atherosclerosis, Angina, Heart Failure, Advanced Imaging Technologies. We used Boolean operators AND, OR, NOT and developed MeSh Terms to run our search on the database. Below is the detailed information of search strategy in Prisma flow chart.

Figure 1. Flow diagram for PRISMA.



Source: own elaboration (2024)

RESULTS AND DISCUSSION

The literature review employed a systematic approach, screening 902 records and assessing 504 reports for eligibility. From a total of 1,672 database entries, 27 high-quality papers were selected. Rigorous criteria excluded outdated and irrelevant studies, such as those that explain heart conditions other than CAD, ensuring a focused exploration of recent interventional cardiology advancements for coronary artery disease.

Table 1. Summary of findings (Selected Papers)

#	Author(s)	Date	Title
1	Centers for Disease Control and Prevention	2021, July 19	Coronary Artery Disease
2	Cleveland Clinic	n.d.	Coronary Artery Disease
3	Centers for Disease Control and Prevention	2023, May 15	Heart Disease Facts
4	Van Der Wall, E. E., Vliegen, H. W., De Roos, A., Brusckhe, A. V.	1995	Magnetic Resonance Imaging in Coronary Artery Disease
5	Secretariat, M. A.	2010	Stress Echocardiography for the Diagnosis of Coronary Artery Disease: An Evidence-Based Analysis
6	Joshi, H., Shah, R., Prajapati, J., Bhangdiya, V., Shah, J., Kandre, Y., Shah, K.	2016	Compared to Conventional Angiography, the Diagnostic Accuracy of Computed Tomography Angiography in Patients Undergoing Noncoronary Cardiac Surgery
7	Singh, V., Kalimuthu, L. M., Mishra, A., Ora, M., Gambhir, S., Nazar, A. H.	2023	Role of Positron Emission Tomography Cardiac Perfusion Imaging in Clinical Management, Prognosis, and Risk Stratification of Cardiovascular Disease
8	Sun, Z., Liu, Y., Zhou, D., Yan, Q.	2012	Use of Coronary CT Angiography in the Diagnosis of Patients with Suspected Coronary Artery Disease
9	Abubakar, M., Javed, I., Rasool, H. J., Raza, S., Basavaraju, D., Abdullah, R., Ahmed, F., Salim, S. S., Faraz, M. A., Hassan, K. M., Hajjaj, M.	2023	Advancements in Percutaneous Coronary Intervention Techniques: A Comprehensive Literature Review of Mixed Studies and Practice Guidelines
10	Bansal, A., & Hiwale, K.	2023	Updates in the Management of Coronary Artery Disease: A Review Article
11	Green, K. D., Lynch, D. C., Chen, T. P., & Zhao, D.	2013	Combining PCI and CABG: The Role of Hybrid Revascularization
12	Mass General Brigham	n.d.	Gene and Cell Therapy Institute
13	El-Tallawi KC, Aljizeeri A, Nabi F, Al-Mallah MH.	2020	Myocardial Perfusion Imaging Using Positron Emission Tomography
14	Truong, Q. A., & Gewirtz, H.	2014	Cardiac PET-CT for Monitoring Medical and Interventional Therapy in Patients with CAD
15	Shahjehan, R. D., & Bhutta, B. S.	2023, August 17	Coronary Artery Disease
16	Zhao, Z., Dong, S., Sun, T., Han, K., Huang, X., Ma, M., Zhou, Y.	2023	The Association between Higher FFAs and High Residual Platelet Reactivity among CAD Patients Receiving Clopidogrel Therapy
17	Fortunato, G. A., & Davierwala, P. M.	2023	The Current Role and Future Perspectives of Minimally Invasive Coronary Artery Bypass Grafting
18	Oosterlinck, W., Algoet, M., & Balkhy, H. H.	2023	Minimally Invasive Coronary Surgery: How Should It Be Defined?

19	Taggart, D. P.	2024	PCI versus CABG in Coronary Artery Disease
20	Assari, A., Al Bukairi, M., & Al Saif, R.	2024	Micro-Computed Tomography Applications in Dentistry
21	Gill, J. K., Rehisa, S. K., Verma, E., Sareen, N., & Dhingra, S.	2024	Stem Cell Therapy for Cardiac Regeneration: Past, Present, and Future
22	Sapna, F. N. U., Raveena, F. N. U., Chandio, M., Bai, K., Sayyar, M., Varrassi, G., Mohamad, T.	2023	Advancements in Heart Failure Management: A Comprehensive Narrative Review of Emerging Therapies
23	Balavigneswaran, C. K., Selvaraj, S., Vasudha, T. K., Iniyan, S., & Muthuvijayan, V.	2023	Tissue Engineered Skin Substitutes: A Comprehensive Review of Basic Design, Fabrication Using 3D Printing, Recent Advances and Challenges
24	Pinsdorf, D., Messiha, D., Petrikovich, O., Bahar, M., Steinmetz, M., Mahabadi, A. A., Rammos, C.	2023	Differences in Treatment Strategies for LDL-Cholesterol Reduction in a University Lipid Clinic vs. Standard Care Apart from the Use of PCSK9 Inhibitors
25	Liu, L., Zhang, M., Zhang, M., Zhang, L., Xu, L., & Song, X.	n.d.	Improved Evaluation of Coronary Artery Diseases from Patients with Coronary Calcification Utilizing CT-FFR: A Comparative Study Against CCTA
26	Kim, C., Song, J. H., & Kim, S. H.	2023	Validation of Wearable Digital Devices for Heart Rate Measurement During Exercise Test in Patients With Coronary Artery Disease
27	Rivera, F. B., Cha, S. W., Aparece, J. P., Rocimo, A., Ong, B. A., Golbin, J. M., Shah, N. P.	2023	Sex Differences in Cardiovascular Outcomes and Cholesterol-Lowering Efficacy of PCSK9 Inhibitors: Systematic Review and Meta-Analysis

Note. Own elaboration with the research data (2024)

Diagnostic Advancements in Cardiology

Magnetic Imaging Technique Mri

MRI imaging is a crucial imaging technique for coronary artery disease (CAD) evaluation, focusing on acute myocardial ischemia and infarction, sequelae assessment, bypass grafts, and coronary artery visualization. It accurately assesses infarct size using T2 relaxation times and paramagnetic contrast agent Gd-DTPA, distinguishing ischemic from normal myocardium. Clinical studies confirm T1 and T2 alterations in infarcted tissue. Additionally, cine MR imaging detects regional myocardial dysfunction through abnormal wall motion and thickening, aiding in viability assessment. Ultrafast MRI imaging with contrast agents allows noninvasive myocardial perfusion assessment, which is crucial in CAD diagnosis. Future advancements aim to enhance speed and accuracy, potentially challenging current diagnostic modalities (Van Der Wall, 1995). The success percentage of MRI in diagnosing CAD varies depending on the specific technique used and the patient population. Stress cardiac MRI using perfusion analysis yielded a sensitivity of 91% and specificity of 79% for detecting CAD (Secretariat, M. A. 2010).

Echocardiography ECG In CAD Patients

Echocardiography utilizes ultrasound technology to visualize the heart's structures and function, with recent advancements including 3D imaging, strain imaging for assessing myocardial mechanics, contrast-enhanced techniques for improved delineation of cardiac structures, and artificial intelligence integration for enhanced interpretation efficiency and accuracy. Secretariat 2010. suggested that while evaluating its effectiveness, stress echocardiography shows a sensitivity of approximately 80%, indicating that it correctly identifies CAD in about 80% of patients who have the condition. Similarly, its specificity is around 84%, meaning it accurately rules out CAD in about 84% of patients who do not have the condition (Secretariat, M. A. 2010).

Position Emission Tomography

PET MPI is an important clinical tool for CAD management, attributing to the early detection of abnormalities and improved assessment capabilities. PET is perfect tool for determining the absolute MBF (Myocardial Blood Flow), especially in atherosclerosis, multivessel disease, and microvascular dysfunction. Imaging technology capable of tracing a layer of ridges in blood vessels allows for identifying flow-limiting effects under exercise (stress-induced hyperemic flows). As a result, it successfully detects coronary artery disease (CAD). The MPI obtained from PET confirms high sensibility and specificity for assessment of CAD detection in addition to superiority in MBF assessment and Myocardial Flow Reserve MFR. Besides the PET engine being able to measure the ischemia risk, it also helps stratify the patients with 70% stenosis or more. PET surpasses SPECT in these indicators, but the latter implicates it only in listing the focal ischemia rather than in atherosclerosis, epicardial stenosis, and microvascular dysfunction. PET's timing resolution power indicates the difference between the two modalities and the accurate CAD diagnosis and risk stratification. The comparison drawn with Coronary computed tomography angiography CTA stresses PET's huge advantage in identifying functional stenoses with higher management priority by underlining the value of PET in CAD management (Singh., 2023). Prevalence of the heart attack has been studied through radiologic imaging of myocardial perfusion (MPI). Research was held to know efficacy of PET MPI, it was found to have a 90 percent positive detection of at least one coronary artery with >50% obstruction and 89 percent negative findings in specificity. Furthermore, PET MPI makes correct predictions in detecting who has LVEF of 40% or lower with a positive predictive value of 94% and the people with LVEF of > 40% with a negative predictive value of 73%, resulting in the diagnostic accuracy of 90%. (Truong., 2014)

Coronary Computed Tomography Angiography (Ccta)

Coronary computed tomography angiography (CCTA) has advanced the diagnostic process of coronary artery disease (CAD) previously reliant as invasive techniques, and now due to its capability of non-invasively understanding the anatomy of the CAD has now revolutionized. To that end, the non-invasive imaging technique CCTA depicts the arterial anatomy without the necessity of puncturing it using a catheter.

Conventionally, invasive coronary angiography has been the best approach for CAD diagnosis because it has a higher superior contrast and resolution of time and space. Also, this procedure was connected with risks, including unacceptable invasiveness, high costs, possible complications, and even death. Since its revalorization to noninvasiveness, multiple studies have revealed CCTA as a very predictive test, with a higher diagnostic accuracy rate than invasive angiography. Through CCTA, we can reliably detect significant CAD and gain information about luminal changes, plaque structure, and non-stenotic plaques. This feature represents a part of the imaging capabilities of this modality that led to its application in diagnosing CAD. Even though CCTA has demonstrated the best results, some radiation-related problems may occur when applied to human beings. In CCTA, ionizing radiation is used, which means that the risks linked to radiation do exist which can cause cancer. Dose-reduction strategies like ECG-triggered CCTA for prospective radiation exposure are the existing activities to lower these risks. The appropriate clinical application of CCTA is necessary to ensure its use will be wise in patients suspected of CAD. Practitioners should impartially weigh the essential issues of the patient's age, symptoms, and risk profile prior to suggesting a CCTA procedure. Furthermore, we can establish the standards for the clinical requisites of CCTA and the limitations of its overutilization, specifically in low-risk people (Sun et al., 2012). To check CCTA diagnostic accuracy rate, Joshi et al. (2016) found that CT coronary angiography has a sensitivity of 100% and a specificity of 91.30% for diagnosing coronary artery disease. While the negative predictive value was 100%, indicating CCTA effectiveness in ruling out CAD, the positive predictive value was 50%, suggesting some uncertainty in positive results (Joshi et al., 2016).

LATEST ADVANCES TO Interventional Cardiology in Coronary Artery Disease (CAD)

Interventional cardiology is indeed a possible alternative to surgery in the management of Coronary Artery Disease CAD that makes the medical treatment of heart problems through catheterization possible. Assigned group of heart interventions undergo open heart surgery in the least possible way, for example, angioplasty and stenting, to fix the vessels that are impaired, open the tightened arteries, and recover the heart muscle function. Interventional cardiology has become convenient option when it comes to the diversity of cardiovascular diseases, for example, atherosclerotic cardiovascular disease through the administration of advanced diagnostic and treatment technologies. This approach also helps patients skip heart surgery and instead stands for the road to better healing outcomes, which makes it a huge step in cardiac care (Chepeleva., 2023). Bioresorbable Vascular Scaffolds (BVS) imply a jump in stent technology as they enable arterial healing with a flair of vanishing after some time. The long-term purposes of this technology are to avoid the complications associated with permanent stents, complications like stent thrombosis or stenosis, by providing a treatment that removes the foreign material from the affected artery, which will return a healthy channel. While important for their safety and effectiveness, one should remember that these procedures still have to be checked by randomized clinical trials to see how effective they are compared with drug-eluting stents. DES have demonstrated their role in reducing restenosis cases rather than the BMS, which are the predecessors of stents without cover. With long-term deposition of the anti-proliferant drugs, DES prevents excessive scar tissue formation that can result in vessel re-narrowing. From the first to the second-generation DES development, improvement has been reached regarding stent design and the selection of drug and drug coating components, making them safer and more effective. First-generation DES, however, are being less prescribed due to their tendency to undergo restenosis more frequently and the higher risk of stent thrombosis to some extent.

Advancements in Procedural Techniques and Equipment

Intravascular Imaging Technologies

Innovations like Intravascular Ultrasound (IVUS) and Optical Coherence Tomography (OCT) improve the precision of stent placement and optimization by providing detailed images of the coronary arteries. This allows for better assessment of lesion characteristics, more accurate stent sizing, and confirmation of optimal stent expansion and apposition. These advancements reduce procedural complications and enhance the long-term success of percutaneous coronary intervention PCI. PCI is a minimally invasive procedure used to treat narrowed or blocked coronary arteries, typically caused by coronary artery disease (CAD)

Robotic-Assisted Pci

Since robotics in PCI have arrived, surgery procedures have enhanced precision, stability, and control, potentially reducing operator radiation exposure and improving procedural outcomes. Percutaneous Coronary Intervention PCI in robotic systems allow for precise manipulation of catheters and stents, which may lead to safer and more effective treatments, particularly in complex cases.

Telemedicine

Expanding access to PCI through telemedicine is also a game-changer for patients in remote areas. Telemedicine facilitates remote patient monitoring, consultation, and even guidance during procedures, ensuring that more patients receive timely and expert care. These advancements in PCI, from cutting-edge stent technologies to innovative procedural techniques and equipment, underscore the dynamic nature of interventional cardiology. By continuously improving the safety, effectiveness, and long-term outcomes of PCI for CAD patients, these innovations reflect the commitment of the medical community to enhance patient care and combat one of the leading causes of morbidity and mortality worldwide (Abubakar et al., 2023).

Post-PCI Care and CAD Management Advancements

More innovative antiplatelet agents, the PCSK9 inhibitors for fat control, and other medical treatments are the major developments beyond PCI, which form better post-PCI post-care and whole Coronary Artery Disease (CAD) management methods. These pharmacological interventions, together with the personalized medicine strategy of genetic testing for guiding therapy, exemplify the workflow of a transition towards new practices and approaches, which are more effective, tailored, and complex.

Newer Antiplatelet Agents

The step-changing advent of the recently developed antiplatelet agents, including prasugrel, ticagrelor, and cangrelor, is a novelty in the management techniques of patients going for PCI and those suffering from ACS. Unlike clopidogrel, this new class of anti-platelet agents does this just as well or even a little better by fast kick-in, which is highly efficient and results in fewer cardiovascular events than the conventional antiplatelet agents. Ticagrelor demonstrated potency in the prevention of death due to vascular diseases or myocardial infarction (MI) or stroke by achieving a 28% reduction in this class of patients with acute coronary syndrome (ACS) in comparison to clopidogrel. Nevertheless, for better efficacy, it entails a higher risk of bleeding, which has led to the development of guidelines on patient screening and risk-adapted therapy. This progressive shift shows the need to combine efficacy and safety while adopting the anti-platelet approach, highlighting the evolution of the patient into more detail-scheduled and personalized risk management in CAD.

PCSK9 Inhibitors For Cholesterol Management

One of the recent approaches is the introduction of PCSK9 inhibitors, namely evolocumab and alirocumab, as a novel way of lipid management for patients suffering from hypercholesterolemia, not responding to statins, or having extremely high cardiovascular event risk. These medications block the protein called PCSK9, which prevents LDL-C from being removed from the blood circulation (Rivera., 2023). As a result, LDL-C levels may drop significantly below those obtainable with statin treatment alone and consequently diminish major adverse cardiovascular events. By their introduction, specialized doctors have established a new front in the war against high-risk CAD, where on top of other strategies, they use a more aggressive modality targeting the lipids - a most critical factor in the progression of CAD. Nowadays, CAD management involves the use of antiplatelet agents, and cholesterol control drugs are no longer the only ways to prevent the development of the disease. For instance, Ranolazine has a novel method of treating chronic angina by inhibiting late sodium currents in the myocardium, which in turn helps relax cardiac activity and reduce the anginal symptoms. Such drugs, together with the other ones the e, are examples of the expansion of treatment methods to manage the many-sided nature of CAD - from the symptom relief that is widely implemented now to the disease mechanisms addressed (Pindorf., 2023).

Other Personalized Medicine Approaches

In genetic testing, individualized medicine in managing CAD has gained a new lease of life, specifically with antiplatelet therapy. Genetic alterations, including those involving the CYP1C19 enzyme, are responsible for the propagation of the drug clopidogrel in an amount that can differ for many people (Zaho, 2023). This can lead to variable drug efficacy and increased risk of cardiac events in certain individuals. Genetic testing enables us to select the drug that can best target a platelet abnormality by comparing different drug effects with a patient's genotype. This strategy, in particular, leads to an increase in the effectiveness of the therapy and, at the same time, diminished chances of adverse reactions, thus strengthening the concept of the precision medicine approach in cardiovascular care.

Minimally Invasive and Hybrid Surgical Approaches

Minimally Invasive Cabg Techniques

Minimally invasive Coronary Artery Bypass Grafting or CABG techniques have evolved as a response to the need for less invasive surgical options, reducing the morbidity associated with traditional open-heart surgery (Fortunato. 2023). These techniques involve smaller incisions, often avoiding a full sternotomy and sometimes employing robotic assistance for precision. These techniques can lead to shorter hospital stays, quicker recovery times, reduced pain, and a lower risk of infection-related complications. They are particularly beneficial for patients who are poor candidates for traditional surgery

due to various risk factors (Oosterlinck, 2023).

Combination Of PCI And CABG:

Composed of a hybrid method of revascularization, it brings the qualities from both worlds, the durability and long-term patency that is used in CABG, along with the quicker recovery and less invasive approach that is utilized in methods of PCI for non-LAD lesions (Taggart, 2023). The candidate for ideal hybrid procedures may be among patients with multivessel CAD, especially when compared to others where one vessel may find CABG to be the answer and the other will concern PCI. Factors favoring this strategy are Lesions of the whole left coronary artery, which is 30%, diabetes, systolic dysfunction, and specific anatomy of the heart muscles. The surgical approach of avoiding full sternotomies and using drug-eluting stents (DES) for PCI ensures a shorter recovery time and a lower complication rate than traditional procedures only. This method limits the influence of treatment on a patient with CAD, and, at the same time, it has the opportunity to accomplish a cure. The hybrid techniques that are used not only serve as a completely lasting remedy for degenerative changes but also help patients to rebound back to their day-to-day activities faster with fewer aches after the operation and a lower chance of postoperative trouble and complications that might occur over time. The breakthrough of endovascular surgery and hybrid approach in coronary revascularization paved the way for patient-oriented treatment. This approach guarantees the dual goal of CAD healing efficiency and patient satisfaction throughout the recovery period. Medical providers can categorize or personalize the treatments based on the needs of each patient, hence better results and improved quality of life by using less invasive medical procedures as an option. Other research and technological developments in these practices will continue to refine them, which will be accessible to a large population in a few years (Green, K., 2013).

Enhancing CAD Post-Treatment Surveillance with Cutting-Edge Technologies

In post-treatment surveillance for coronary artery disease (CAD), the deployment of cutting-edge imaging modalities and digital health technologies is reshaping patient monitoring and management. High-definition imaging tools like Optical Coherence Tomography (OCT) and Fractional Flow Reserve (FFR) derived from computed tomography (CT-FFR), alongside wearable devices featuring advanced biosensors, are setting new standards in precision, early detection, and personalized care (Assari, 2024).

OPTICAL COHERENCE TOMOGRAPHY (OCT) IN-STENT EVALUATION

OCT offers tenfold higher resolution than intravascular ultrasound (IVUS), allowing cardiologists to examine stent apposition closely, detect strut coverage, and identify signs of neoatherosclerosis within the stent—a critical factor in predicting long-term patency and preventing stent thrombosis. For instance, using OCT can precisely measure the malposition of stent struts to the vessel wall, which is crucial for adjusting antiplatelet therapy in the early postoperative period (El-Tallawi, 2020).

CT-FFR's Role in Non-invasive Functional Assessment

CT-FFR is a non-invasive alternative to traditional catheter-based FFR because it provides a functional assessment of coronary lesions using standard CT angiography. Combining anatomical and functional data, CT-FFR accurately predicts the hemodynamic significance of intermediate lesions without requiring invasive procedures. Studies demonstrated that CT-FFR's efficacy in guiding clinical decisions significantly reduces unnecessary angiographies by up to 61% when CT-FFR is utilized in the evaluation process (Iiu., 2023).

Potential of Wearable Biosensors and Remote Monitoring Platforms

Wearable biosensors have now become capable of continuous monitoring of vital parameters and have shown promising results in early detection and management of cardiac events post-CAD treatment (kim., 2023). Devices like the Zio patch, an extended-wear ECG monitor, offer a glimpse into the future of cardiac surveillance by detecting arrhythmias more accurately than traditional Holter monitors. Integrating wearables with AI-driven analytics platforms can predict adverse events before they become life-threatening, facilitating timely intervention. On the other hand, remote monitoring platforms integrated with patient data from wearables and electronic health records can provide a comprehensive view of the patient's health status, enabling personalized care plans and timely adjustments. Platforms like HeartFlow offer a combined analysis of CT images and FFR data, creating a detailed 3D model of the patient's coronary arteries to assess the impact of arterial blockages on blood flow, significantly improving the accuracy of CAD treatment planning (El-Tallawi, 2020).

Emerging Therapies and Future Directions in CAD Treatment:

Emerging therapies in treating coronary artery disease (CAD) are pushing the boundaries of current medical practices, introducing innovative approaches that could dramatically transform patient care. Among these, gene therapy, stem cell therapy, and novel anti-inflammatory therapies stand out for their potential to address the underlying causes of CAD, promote myocardial regeneration, and mitigate the effects of atherosclerosis (Gill, 2024).

Gene Therapy For Angiogenesis

Recent advancements in treating coronary artery disease (CAD) through gene therapy are efficient, particularly in applying nanoparticles (NPs) to stem cell-based therapy. NPs use a groundbreaking approach to enhancing the delivery of therapeutic genes into stem cells because their main aim is to improve their survival, function, and the secretion of beneficial factors in the ischemic myocardium. Innovative gene vectors such as liposomes and polymers are being explored for their efficiency in gene delivery, reduced cytotoxicity, and improved targeting specificity. All these are the latest advancements that not only signify a move towards non-viral gene delivery methods, addressing previous safety concerns associated with viral vectors but also highlighting the potential for significantly improved transfection efficiency. This novel approach underlines a strategic shift in regenerative medicine, offering new hope for more effective, targeted, and safe treatments for patients suffering from CAD (Sun et al., 2012).

Stem Cell Therapy For Myocardial Regeneration

The advances in stem cell therapies to treat CAD reflect the evolution of this type of disease in terms of cardiac care. The therapy commonly consists of repairing the damage in myocardial tissue, improving cardiac function as well as decreasing the morbidity and mortality induced by CAD. We have undergone significant advancements in gathering the necessary knowledge of stem cell applications, from lab to clinical trials, in the past decade. MSCs are mesenchymal descendants of stem cells that possess great immunomodulating and tissue repair abilities and, therefore, emerged as a leading regenerative therapy. MSCs may be sourced from the bone marrow, fatty tissue, or the cord of the umbilical cord, a non-invasive method compared to other types of stem cells. In the trials, MSC therapies demonstrated improved heart perfusion and left ventricular function in patients with CAD (Sapna, 2023). Genetic engineering or preconditioning techniques enhance the MSCs function, reducing their mortality while increasing their survivability, growth, and angiogenic factor release in compromised myocardial tissues after transplantation. The findings of induced pluripotent stem cells (iPSCs) represent an innovative method for fabricating regenerative medicine for heart disease. The iPSCs, generated by transforming adult somatic cells into a pluripotent state, may give rise to various target cells, such as cardiomyocytes (CMs). Here, two main assets of this technology are mentioned: embryonic stem cell ethical concerns are bypassed, and personalized medicine promises to minimize patient rejection. The progress of iPSC technology includes upgrading protocols for efficient total transformation of iPSCs into a fully functional center of the muscle, combined with studies that reveal the therapeutic correction potential of iPSC-derived CMs in the treatment of cardiac muscle injury.

As an alternative to implanting stem cells derived from patients, cardiac progenitor cells (CPCs) are also another potential option for cardiac repair. CPCs stay within the heart, and they're able to express several kinds of cardiac cells, including cardiomyocytes, endothelial cells, and smooth muscle cells. Our studies could be crucial in improving cardiac regeneration through multifunctional delivery and precise control of CPCs. The recent research explores the synergic effect between CPC therapy and biomaterials that incorporates improvement in the loss of cells and their survival and infiltration into the host myocardium. Exosome therapy is the state-of-the-art modality within the arsenal of stem cell-based therapy that employs these latter's paracrine signaling mechanisms for cardiac regeneration. Exosomes are extracellular fluids secreted by cells that have nucleic acids, proteins, and lipids that signal intercellular communication. It has been proved that stem cell-derived exosomes in preclinical models of CAD play an important role in angiogenesis, apoptosis reduction, and cardiac repair by generating new vessels, suppressing cell death, and promoting the regeneration of cardiac tissue, respectively. In this method, there is an opportunity to restore defective functions without rejecting the immune system and tumor formation. The use of stem cell therapies in combination with biodegradable and biotechnology-mediated tissue engineering has contributed greatly to aiding and repairing impaired myocardial tissue. Scaffold-dependent and scaffold-free approaches are designed to serve as a habitat for the stem cells, prolong their survival, and give them a suitable environment for integrating and optimizing the cardiac condition. The introduction of tissue engineering has advanced the days when allograft and autograft were the only cell sources for the heart (Balavigneswaran., 2023). These include the development of bioengineered cardiac patches, injectable hydrogels, and 3D-bio-printed tissues that can be implanted directly at the site of injury, which provide stem cells in an environment incentive the tissue repair and improve the function of the With better cell delivery techniques being devised, other challenges like the longevity of the revised cells and manufacturing processes that can be applied to humans to solve gaps that are still existing.

Anti-Inflammatory Therapies Targeting Atherosclerosis

Innovative anti-inflammatory treatments aim to address the underlying causes of atherosclerosis and CAD, i.e., the process that is involved in coronary artery disease, by targeting the inflammation process that contributes to the same. Focusing on the molecular and cellular mechanisms that cause arterial wall inflammation, researchers try developing treatments that slow and even reverse plaque accumulation. It is possible that this could prevent the CAD from worsening and the possibility of acute coronary syndromes, such as acute cardiac arrests (Mass General Brigham., n.d).

CONCLUSIONS

It is concluded that recent advancements in interventional cardiology for Coronary Artery Disease (CAD) have transformed CAD dramatically with significant improvements and advancements in diagnostics, interventions, post-procedure care as well as emerging therapies. Innovative diagnostic tools like MRI and CCTA enable precise detection and assessment of CAD, guiding successful interventions. It is concluded that bioresorbable scaffolds and drug-eluting stents, alongside robotic-assisted procedures all these procedures have boosted the efficacy of percutaneous coronary interventions and in CAD. Post-procedure care benefits from new antiplatelet agents and personalized medicine strategies are seen to reduce future cardiovascular risks. Researchers, scientists and medical experts are working on promising therapies like gene and stem cell treatments target CAD's root causes, offering hope for comprehensive disease management. There is a journey of evolution and revolutionization towards more personalized approached and technology-driven care that will drive best management outcomes.

Main limitations of the study and future research

The main theoretical and methodological limitations of this literature review lie in the possibility of a kind of selection "bias" in the inclusion of studies for two main reasons: 1) the absence of gray literature; 2) the concentration only on studies published in English. Although we adopted a mainstream perspective of systematic review, neglect of these two points could directly or indirectly result in an incomplete or partial representation of innovations in interventional cardiology for the treatment of CAD. Furthermore, the lack of quantitative analysis of the data and the need for a systematic critical evaluation of the quality of the studies reviewed may limit the scope of conclusions drawn. We hope this first approach contributes to generating new agendas and topics that guide more in-depth research. For future studies, it would be essential to conduct research that addresses the aforementioned limitations and provides a more discriminating evaluation of innovations in interventional cardiology (whether from a qualitative or quantitative point of view) and their impact on the treatment and management of coronary artery disease. Finally, emerging solutions that do not yet comply with sufficient replications and verifications for approval can also be the subject of new research.

REFERENCES

- Abubakar, M., Javed, I., Rasool, H. J., Raza, S., Basavaraju, D., Abdullah, R., Ahmed, F., Salim, S. S., Faraz, M. A., Hassan, K. M., & Hajjaj, M. (2023). Advancements in percutaneous coronary intervention techniques: A comprehensive literature review of mixed studies and practice guidelines. *Cureus*. <https://doi.org/10.7759/cureus.41311>
- Assari, A., Al Bukairi, M., & Al Saif, R. (2024). Micro-Computed Tomography Applications in Dentistry. *Open Journal of Stomatology*, 14(1), 32-41.
- Balavigneswaran, C. K., Selvaraj, S., Vasudha, T. K., Iniyan, S., & Muthuvijayan, V. (2023). Tissue engineered skin substitutes: A comprehensive review of basic design, fabrication using 3D printing, recent advances and challenges. *Biomaterials Advances*, 213570.
- Bansal, A., & Hiwale, K. (2023). Updates in the management of coronary artery disease: A review article. *Cureus*. <https://doi.org/10.7759/cureus.50644>
- Centers for Disease Control and Prevention. (2021, July 19). Coronary artery disease. https://www.cdc.gov/heartdisease/coronary_ad.htm
- Centers for Disease Control and Prevention. (2023, May 15). Heart disease facts. <https://www.cdc.gov/heartdisease/facts.htm>
- Cleveland Clinic. (n.d.). Coronary artery disease. <https://my.clevelandclinic.org/health/diseases/16898-coronary-artery-disease>
- El-Tallawi KC, Aljizeeri A, Nabi F, Al-Mallah MH. (2020). Myocardial perfusion imaging using positron emission tomography. *Methodist Debakey Cardiovasc J*, 16(2), 114-121. <https://doi.org/10.14797/mdcj-16-2-114>
- Fortunato, G. A., & Davierwala, P. M. (2023). The current role and future perspectives of minimally invasive coronary artery bypass grafting. *Journal of Visualized Surgery*, 9.
- Gill, J. K., Rehsia, S. K., Verma, E., Sareen, N., & Dhingra, S. (2024). Stem cell therapy for cardiac regeneration: past, present, and future. *Canadian Journal of Physiology and Pharmacology*.
- Green, K. D., Lynch, D. C., Chen, T. P., & Zhao, D. (2013). Combining PCI and CABG: The role of hybrid revascularization. *Current Cardiology Reports*, 15(4). <https://doi.org/10.1007/s11886-013-0351-9>
- Joshi, H., Shah, R., Prajapati, J., Bhangdiya, V., Shah, J., Kandre, Y., & Shah, K. (2016). Compared to conventional angiography, the diagnostic accuracy of computed tomography angiography in patients undergoing noncoronary cardiac surgery. *Heart Views*, 17(3), 88. <https://doi.org/10.4103/1995-705x.192555>
- Kim, C., Song, J. H., & Kim, S. H. (2023). Validation of Wearable Digital Devices for Heart Rate Measurement During Exercise Test in Patients With Coronary Artery Disease. *Annals of Rehabilitation Medicine*, 47(4), 261.
- Liu, L., Zhang, M., Zhang, M., Zhang, L., Xu, L., & Song, X. Improved Evaluation of Coronary Artery Diseases from Patients with Coronary Calcification Utilizing CT-FFR: A Comparative Study Against CCTA
- Mass General Brigham. (n.d.). Gene and cell therapy institute. <https://www.massgeneralbrigham.org/en/research-and-innovation/centers-and-programs/gene-cell-therapy>
- Oosterlinck, W., Algoet, M., & Balkhy, H. H. (2023). Minimally invasive coronary surgery: how should it be defined?. *Innovations*, 18(1), 22-27.

- Pinsdorf, D., Messiha, D., Petrikhovich, O., Bahar, M., Steinmetz, M., Mahabadi, A. A., ... & Rammos, C. (2023). Differences in treatment strategies for LDL-cholesterol reduction in a university lipid clinic vs. standard care apart from the use of PCSK9 inhibitors. *Journal of Clinical Lipidology*, 17(4), 504-511.
- Rivera, F. B., Cha, S. W., Aparece, J. P., Rocimo, A., Ong, B. A., Golbin, J. M., ... & Shah, N. P. (2023). Sex Differences in Cardiovascular Outcomes and Cholesterol-Lowering Efficacy of PCSK9 Inhibitors: Systematic Review and Meta-Analysis. *JACC: Advances*, 2(9), 100669.
- Sapna, F. N. U., Raveena, F. N. U., Chandio, M., Bai, K., Sayyar, M., Varrassi, G., ... & Mohamad, T. (2023). Advancements in heart failure management: a comprehensive narrative review of emerging therapies. *Cureus*, 15(10).
- Secretariat, M. A. (2010). Stress echocardiography for the diagnosis of coronary artery disease: An evidence-based analysis. PubMed Central (PMC) <https://www.ncbi.nlm.nih.gov/pmc/articles/PMC3377563/>
- Shahjehan, R. D., & Bhutta, B. S. (2023, August 17). Coronary artery disease. StatPearls - NCBI Bookshelf. <https://www.ncbi.nlm.nih.gov/books/NBK564304/>
- Singh, V., Kalimuthu, L. M., Mishra, A., Ora, M., Gambhir, S., & Nazar, A. H. (2023). Role of positron emission tomography cardiac perfusion imaging in clinical management, prognosis, and risk stratification of cardiovascular disease. *Indian Journal of Clinical Cardiology*, 4(2), 88–97. <https://doi.org/10.1177/26324636231174797>
- Sun, Z., Liu, Y., Zhou, D., & Yan, Q. (2012). Use of coronary CT angiography in the diagnosis of patients with suspected coronary artery disease: Findings and clinical indications. *Journal of Geriatric Cardiology*, 9(2), 115–122. <https://doi.org/10.3724/sp.j.1263.2012.01041>
- Taggart, D. P. (2024). PCI versus CABG in coronary artery disease. *Vascular Pharmacology*, 107367.
- Truong, Q. A., & Gewirtz, H. (2014). Cardiac PET-CT for monitoring medical and interventional therapy in patients with CAD
- Van Der Wall, E. E., Vliegen, H. W., De Roos, A., & Brusckhe, A. V. (1995). Magnetic resonance imaging in coronary artery disease. 92(9), 2723-2739. <https://doi.org/10.1161/01.cir.92.9.2723>
- Zhao, Z., Dong, S., Sun, T., Han, K., Huang, X., Ma, M., ... & Zhou, Y. (2023). The association between higher FFAs and high residual platelet reactivity among CAD patients receiving clopidogrel therapy. *Frontiers in Cardiovascular Medicine*, 10, 1115142.

Contribution of each author to the manuscript:

Task	% of contribution of each author				
	A1	A2	A3	A4	A5
A. theoretical and conceptual foundations and problematization:	20%	20%	20%	20%	20%
B. data research and statistical analysis:	20%	20%	20%	20%	20%
C. elaboration of figures and tables:	20%	20%	20%	20%	20%
D. drafting, reviewing and writing of the text:	20%	20%	20%	20%	20%
E. selection of bibliographical references	20%	20%	20%	20%	20%
F. Other (please indicate)	-	-	-	-	-

Indication of conflict of interest:

There is no conflict of interest

Source of funding

There is no source of funding

Acknowledgments

There is no acknowledgments